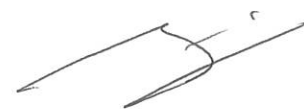


CASO 1



L'imaging delle spondiloartriti



NON SCOLTA

27/142022

CASO 2

La Malattia di Lyme

SM

~~SM~~

SM

SM

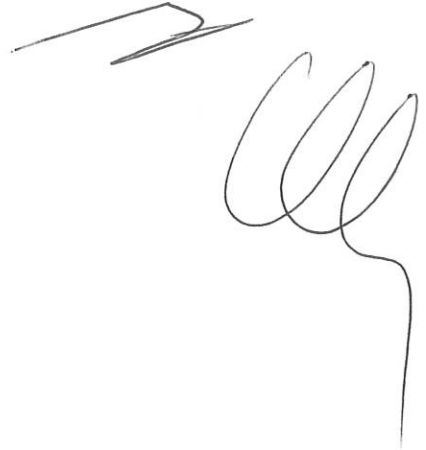
27/12/2022

NON SCELTA

# CASO 3

## La polimialgia reumatica

gms

A large, stylized handwritten mark or signature, possibly consisting of several overlapping loops and a long tail extending downwards.