

PROVA PRATICA "A"

Patient: [REDACTED]
Patient ID: ---
Diagnosis: ---

DOB: [REDACTED]
Exam.: 08/mag/2018
Comment: ---

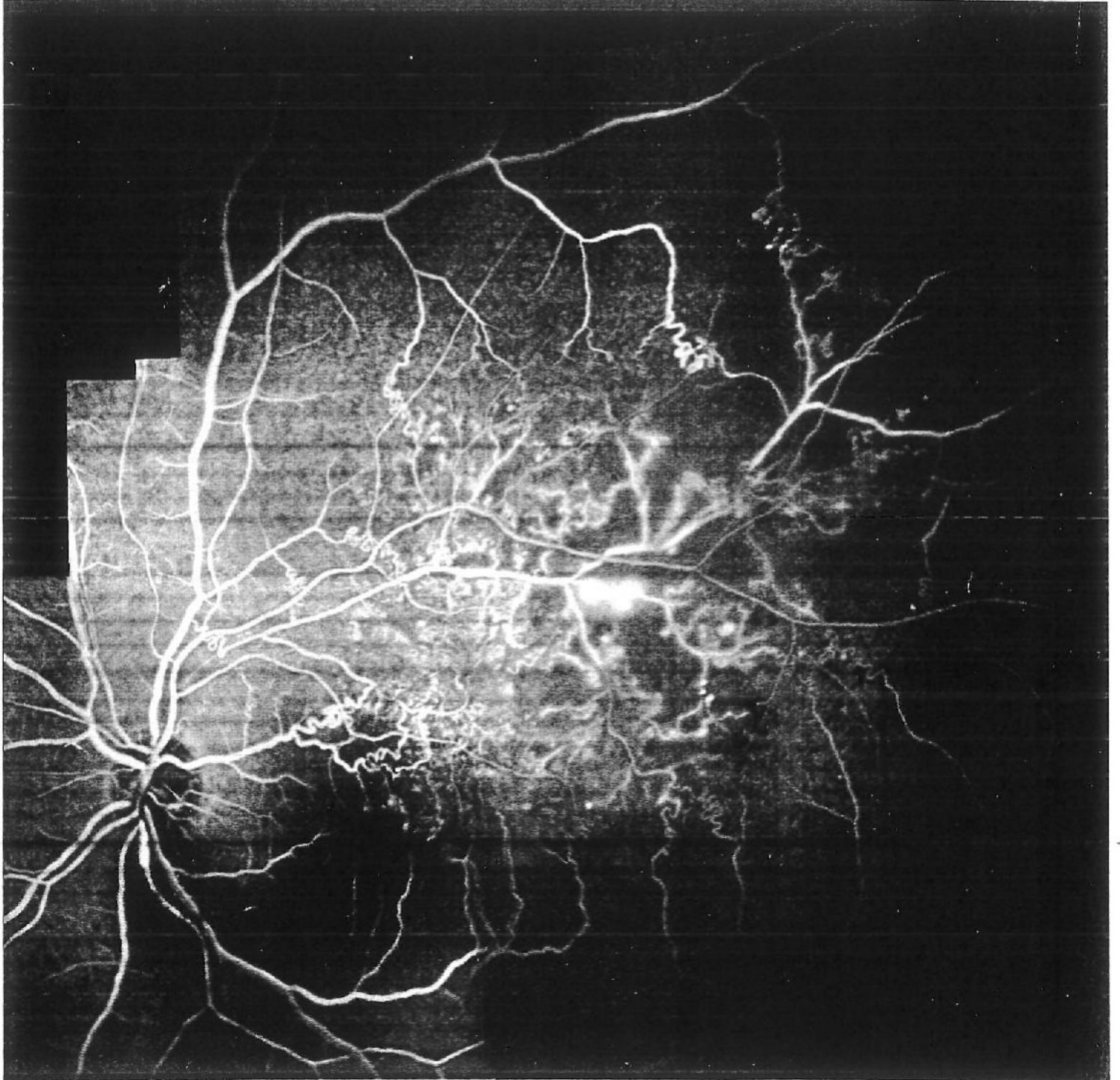
Sex: M

OS

*bolina non
ematte*

[REDACTED]

FA Composite 67°x65° (11) [HS]



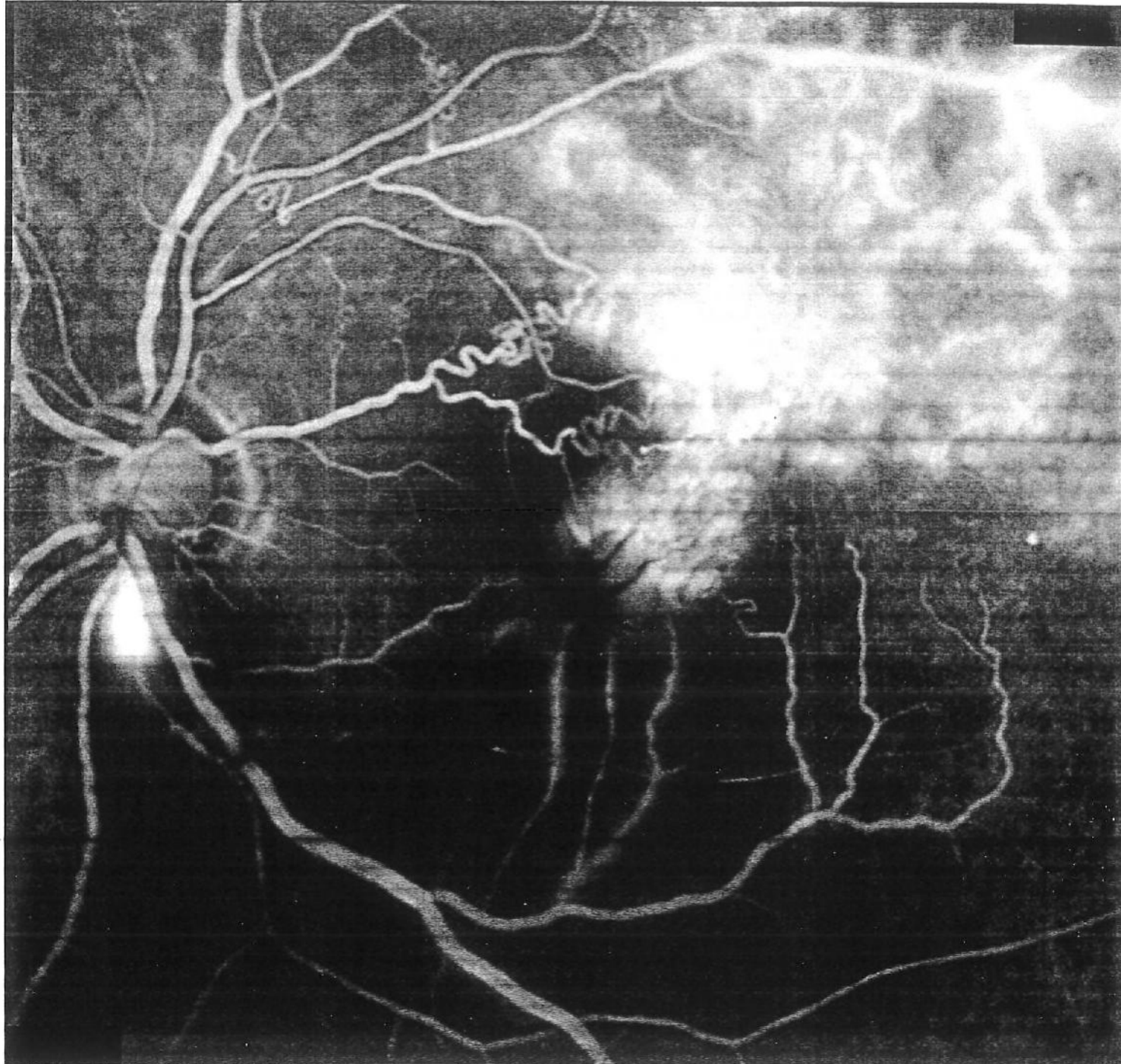
Patient: [REDACTED]
Patient ID: ---
Diagnosis: ---

DOB: [REDACTED]
Exam.: 08/mag/2018
Comment: ---

Sex: M

OS

FA Composite 34°x31° (2) [HS]



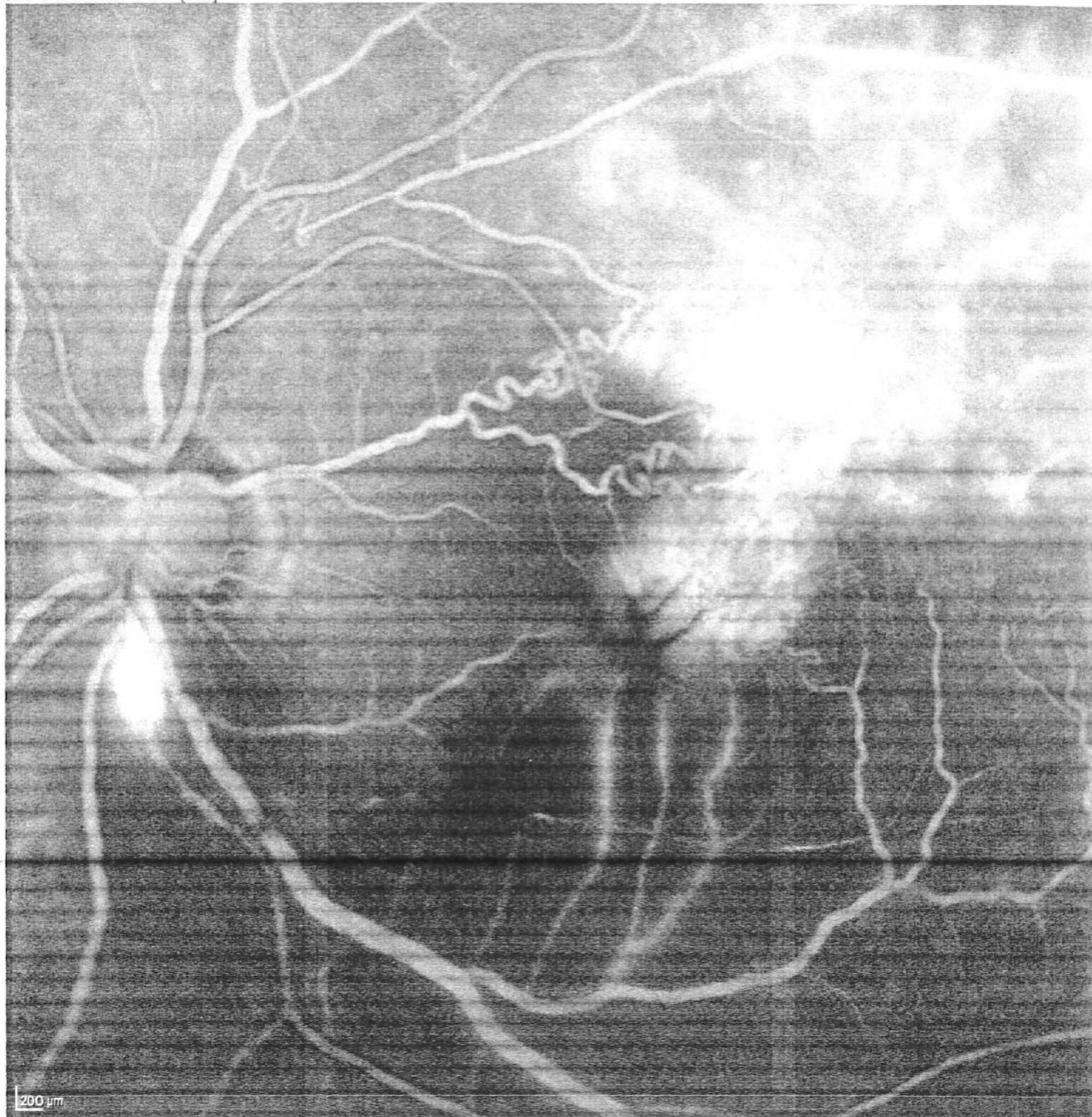
Patient: [REDACTED]
Patient ID: ---
Diagnosis: ---

DOB: [REDACTED]
Exam.: 08/mag/2018
Comment: ---

Sex: M

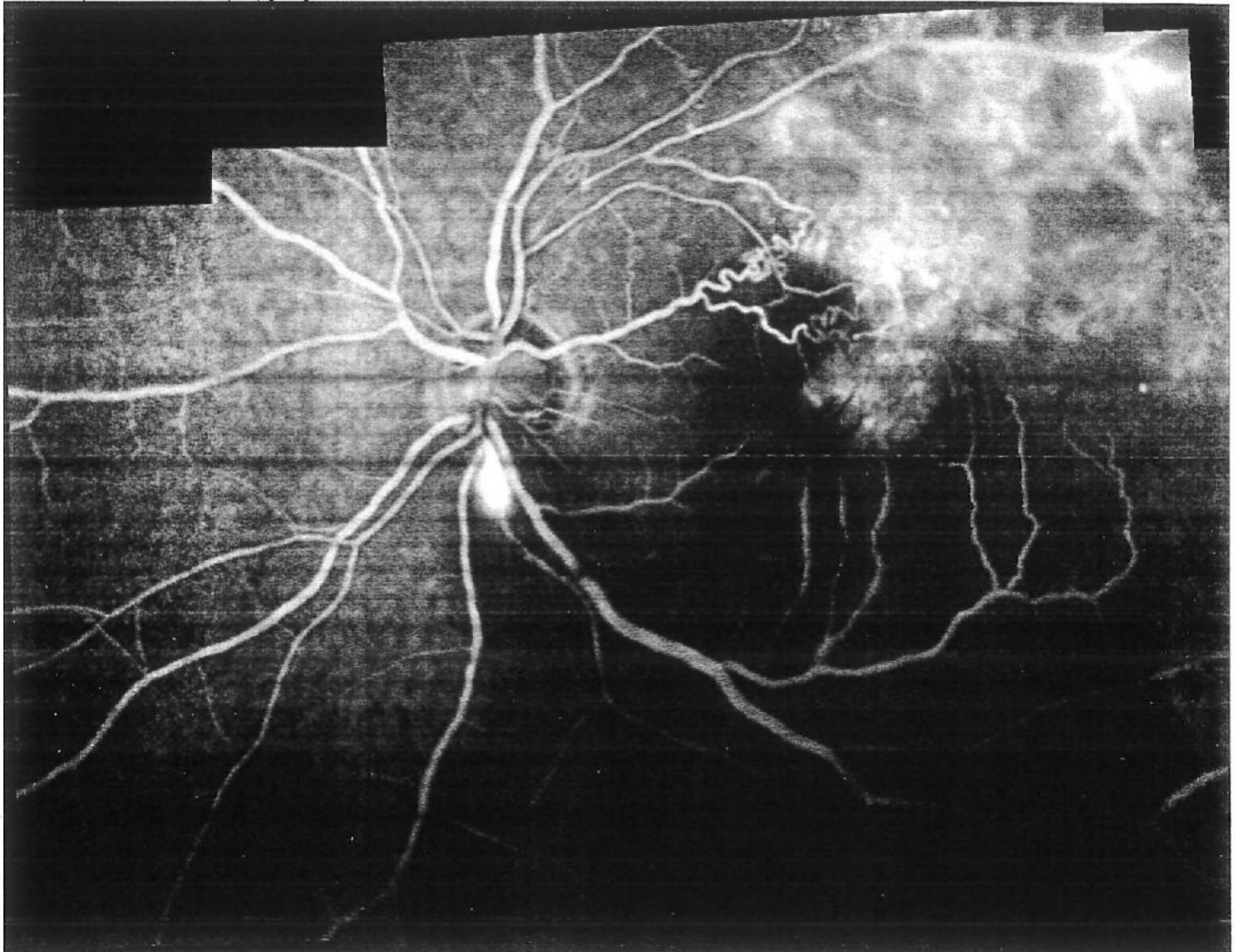
OS

FA 4:13.96 30° ART [HS]



Patient:	[REDACTED]	DOB:	[REDACTED]	Sex:	M	OS
Patient ID:	---	Exam.:	08/mag/2018	Comment:	---	
Diagnosis:	---					

FA Composite 51°x39° (11) [HS]



Patient: [REDACTED]

Patient ID: [REDACTED]

Diagnosis: ---

DOB: [REDACTED]

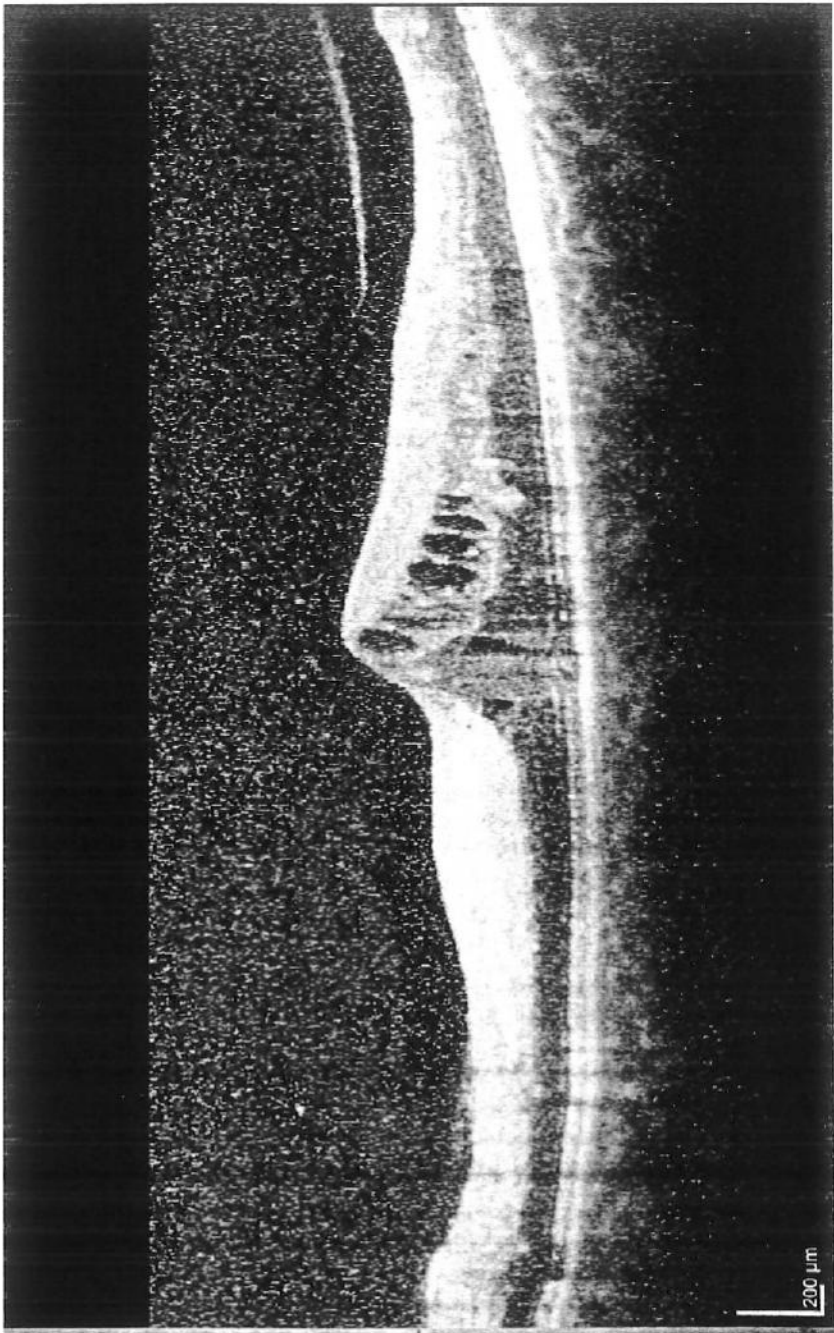

Exam.: 08/mag/2018

Comment: ---

Sex: M

OS

IR 30° ART + OCT 30° (8.7 mm) ART (10) Q: 25 [HS]



OSPEDALE A. MICONE - GENOVA - SESTRIP.
Tel. 010 8498425